

Patient name: \_\_\_\_\_

Dr: \_\_\_\_\_

Date: \_\_\_\_\_

**Pre-appointment information**

Bitewings: Last made:  covered

Pantomograph: Last made:  covered

Last dental visit: \_\_\_\_\_

Chief complaint: \_\_\_\_\_

**Pertinent medical information**

medications reviewed

allergies reviewed

systemic conditions reviewed

**TM joint & extraoral exam**

Patient  reports  denies s/s of TMD.

Bilateral  opening

Unilateral subluxation noted on  closing

Other: \_\_\_\_\_



**Periodontal findings**

Full mouth probe completed

Calculus?  clinical  radiographic

Bleeding on probing present

Radiographic bone loss present

Chart existing restorations & conditions on the odontogram below (in green)

**Soft tissue exam**

intraoral and extraoral soft tissues WNL.

other: \_\_\_\_\_



**Occlusal findings**

General Angle class:  1  2  2E  3

Overbite: \_\_\_\_\_%

Overjet: \_\_\_\_\_mm

Wear:  none  other

VDO:  maintained  lost:

Occlusal plane:  normal  complex:

**Radiographs & scans ordered & made**

4 BWs

Pantomograph

Complete mouth series

Periapicals:

CBCT:

Trios IO scan & post processed

**Comparative testing**

# \_\_\_\_\_ # \_\_\_\_\_ # \_\_\_\_\_ # \_\_\_\_\_

Cold

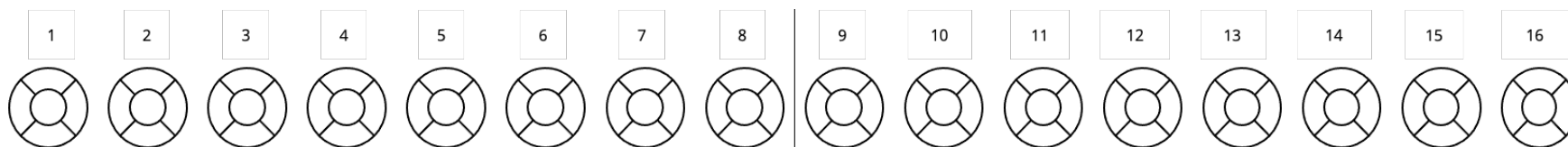
Percussion

Palpation

Tooth slooth

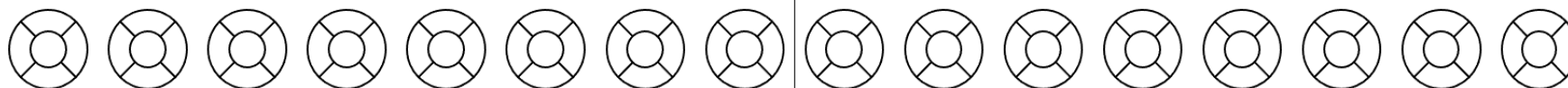


B/F



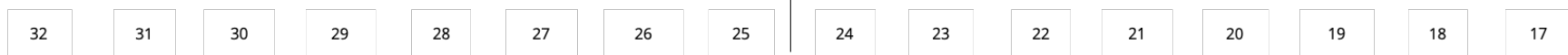B/F

L/P



L/P

B/F



B/F

Patient name: \_\_\_\_\_

Dr: \_\_\_\_\_

Date: \_\_\_\_\_

**Periodontal diagnosis:**

Healthy gingiva	Generalized	Gingivitis	On an intact periodontium	Stage 1	Localized	Grade A	Periodontitis
Incipient gingivitis	Localized		On a reduced periodontium	Stage 2	Generalized	Grade B	
				Stage 3	Molar/incisor pattern	Grade C	
				Stage 4			



**Recommended intervals**

- Cleaning:  3 mo  4 mo  6 mo
- BWs:  12 mo  18 mo  24 mo
- Pantomograph:  7 years

**Recommended gingival treatment**

- Routine prophylaxis
- Super prophy
- SRP 4+:  UR  UL  LR  LL
- SRP 1-3:  UR  UL  LR  LL
- Referral

**Periodontal findings**

- Clinical calculus present.
- Radiographic calculus present.
- Radiographic bone loss.
- Bleeding on probing noted.
- Systemic factors associated with perio.

**Completed today**

- Routine prophylaxis
- Super prophy
- Fluoride rinse
- Fluoride varnish
- 4 BWs
- Pantomograph
- Complete mouth series
- Periapicals:
- CBCT:
- Diagnostic casts (alginate)
- Clinical photographs
- Denture cleaning
- Peridex rinse

**Recommended treatment**

**Checkout information**

- Next visit scheduled
- Financial questions
- Pre-authorization necessary
- Pre-authorization requested
- Prescription
- Referral necessary:

**After visit**

- Existing entered
- Treatment plan entered
- New patient card sent
- Note signed

Reconstruction clinic examination addendum (edentulous, terminal dentition, FMR/PMR)